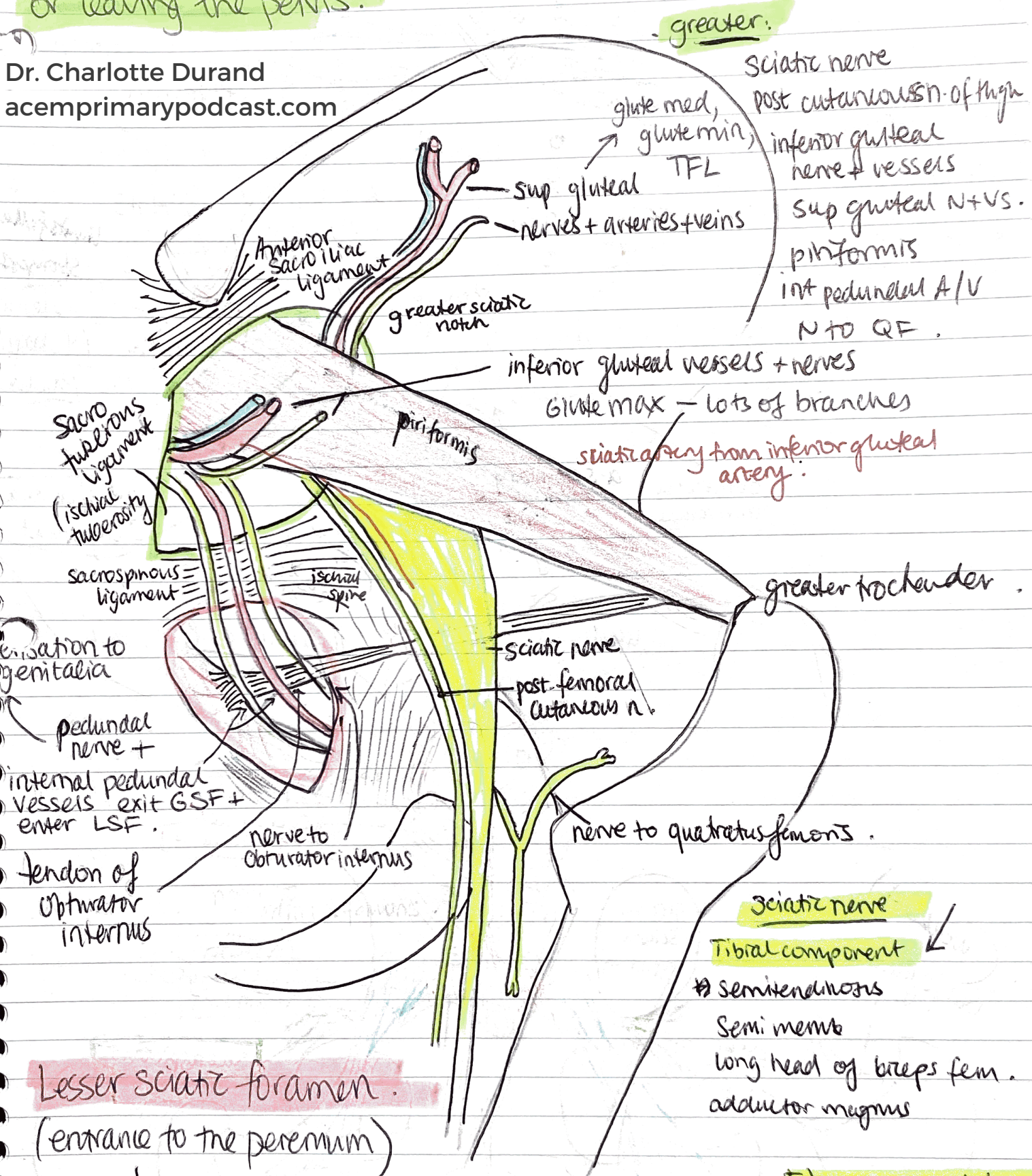


Week 9

Greater Sciatic Foramen: passageway for structures entering or leaving the pelvis.

Dr. Charlotte Durand
acemprimarypodcast.com



Lesser sciatic foramen.
(entrance to the perineum)

- tendon of obturator internus } 1 muscle.
- internal peduncular artery + veins } 2 vessels
- Peduncular nerve } 2 nerves.
- Nerve to obturator internus }

Sciatic nerve

Tibial component

- Semitendinosus
- Semi memb
- long head of biceps fem.
- adductor magnus

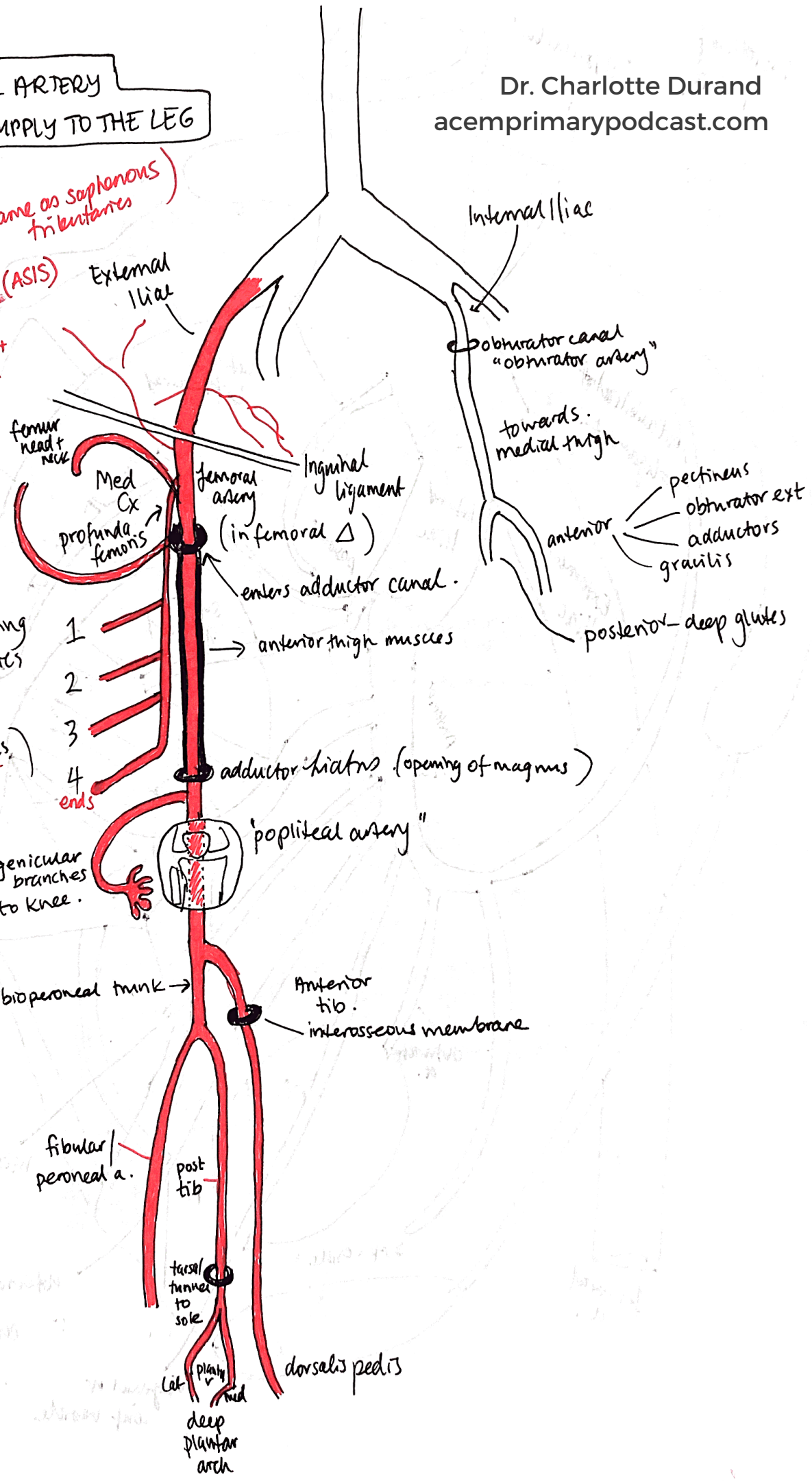
Fib component

- Short head of biceps fem.

FEMORAL ARTERY & BLOOD SUPPLY TO THE LEG

Dr. Charlotte Durand
acemprimarypodcast.com

From femoral artery (same as saphenous tributaries)
 → sup. epigastric
 → sup. circumflex iliac (ASIS)
 → sup. ext. peduncular
 → deep → to scrotum + labia



Lat Cx
lateral thigh muscles

perforating arteries
 (through adductor magnum)

medial + post thigh

genicular branches to knee.

tibioperoneal trunk →

Anterior tib. interosseous membrane

fibular/peroneal a.

post tib

tarsal tunnel to sole

lat plantar
 med
 deep plantar arch

dorsalis pedis

Internal Iliac

obturator canal "obturator artery"

towards medial thigh

anterior
 pectineus
 obturator ext
 adductors
 gracilis

posterior - deep glutes

Femoral Triangle

Dr. Charlotte Durand
acemprimarypodcast.com

